Characterization of the osseointegration of Algipore and Algipore modified with mineralized collagen type I

Matthias C. Schulz, DMD,[a,b] Anja Lode, Dipl. Biol, Dr. rer. Nat,[b] Sabine Wittig, DMD,[a] Bernd Stadlinger, MD, DMD,[a,b] Eberhard Kuhlisch, Dipl. Math,[c] Uwe Eckelt, MD, DMD, PhD,[a,b] Michael Gelinsky, Dipl. Chem., Dr. rer. nat., PhD,[b] and Ronald Mai, MD, DMD,[a,b] Dresden, Germany
FACULTY OF MEDICINE "CARL GUSTAV CARUS", TECHNISCHE UNIVERSITÄT

Objective. Algipore is a clinically established bone substitute. The present study evaluated the osseoconductive and resorptive characteristics of Algipore modified with collagen type I (ACI).
Study Design. Three defects of 10 × 3 mm were set in the frontal bone of 10 adult female minipigs. One cavity was filled with commercially available Algipore, and the second with ACI. The third cavity was left unfilled and served as reference. After 4 months of healing, the animals were humanely killed. Bone formation and resorption characteristics of the substitutes were evaluated histomorphologically and histomorphometrically using Donath's sawing and grinding technique.
Results. Neither material caused inflammatory reactions. Compared with controls, both substitutes showed significantly higher fractions of trabecular bone (control: 42.2%; Algipore: 58.7%, [$P < .001$]; ACI: 53.6%, [$P = .013$]). After 4 months, the remaining fraction of Algipore was 42.2% and the fraction of ACI was 47.9% ($P = .016$).
Conclusions. The present study demonstrates that the modification of Algipore with collagen I does not show any benefits compared with pure Algipore in small calvarial bone defects in minipigs. (Oral Surg Oral Med Oral Pathol Oral Radiol 2012; 114(suppl 5)(suppl 5):S160-S166)

The treatment of large facial bone defects caused by trauma, cysts, or tumor resection is still a challenge for reconstructive surgery. Different bone substitutes have been tested for application in craniofacial bone defects. Such substitutes need to be chemically inert, easily moldable, mechanically stable, replaceable by living tissue over time, and may not cause immunogenicity or carcinogenicity.[1] Currently, autologous bone grafts are considered to be a "gold standard." Osteogenicity, osteoinduction and osteoconduction, rapid integration, and a lack of immunogenicity are the main properties of autografts.[2,3] However, there are some disadvantages, such as limited amount of bone, donor site morbidity, and increased surgical complexity.[4,5]

These shortcomings led to the development of various bone substitutes in oral and maxillofacial surgery. One clinically well-established bone-grafting material is Algipore. This phycogenic porous ceramic hydroxyapatite was developed by Ewers et al. in 1987.[6] It is obtained from the sea algae, *Corallina officinalis,* by pyrolysis at 500°C and autoclaving. Its interconnecting microporous structure with a specific surface area of 50 m^2/g is similar to bone, which allows the adhesion of osteoblastlike cells, the ingrowth of newly formed bone, and finally the resorption of the grafting material.[7,8] Algipore is clinically established for augmentation of atrophic bone. Healing periods between 6 and 7 months are recommended before implant insertion.[8,9] One approach to reduce the duration of treatment could be to foster resorption of the grafting material and thus bone remodeling. The accelerated formation of native and vascularized bone would allow an earlier implantation. A reduced duration of rehabilitation would imply an increase in comfort for patients requiring augmentation.

To create a material that resembles native bone more closely, it is possible to add organic components of the extracellular matrix. The organic part of the extracellular bone matrix, consisting mainly of collagen type I, is known to stimulate bone cell activities.[10]

Bradt et al.[11] developed a biomimetic process in which collagen fibril assembly and mineralization with hydroxyapatite nanocrystals occur simultaneously. This nanocomposite material—mineralized collagen type I—resembles the extracellular bone matrix in structure and composition and is therefore considered to foster the remodeling process. In vitro studies demonstrated that this artificial bone matrix is degradable by osteoclast-like cells and supports proliferation and differ-

This study was funded by the German Research Foundation DFG (Deutsche Forschungsgemeinschaft).
[a]Department of Oral and Maxillofacial Surgery, Faculty of Medicine "Carl Gustav Carus", Technische Universität, Dresden, Germany.
[b]Centre for Translational Bone, Joint and Soft Tissue Research, University Hospital "Carl Gustav Carus", Faculty of Medicine "Carl Gustav Carus", Technische Universität, Dresden, Germany.
[c]Institute for Medical Informatics and Biometry, Faculty of Medicine "Carl Gustav Carus", Technische Universität, Dresden, Germany.
Received for publication Apr 28, 2011; returned for revision Aug 18, 2011; accepted for publication Sep 11, 2011.
© 2012 Elsevier Inc. All rights reserved.
2212-4403/$ - see front matter
doi:10.1016/j.oooo.2011.09.029

entiation of osteoblasts as well as their precursors.[12-14] Twelve weeks after implantation in rat femur, resorption of major areas of porous mineralized collagen scaffolds and replacement by new bone was demonstrated, indicating the suitability for bone tissue reconstruction[15]; moreover, mineralized collagen was used for the modification of a nanocrystalline hydroxyapatite cement and successfully applied in vivo in a minipig model.[16]

Based on these studies, mineralized collagen type I was added to commercially available Algipore. The intention of this study was to evaluate the osseoconductive and resorptive characteristics of Algipore modified with mineralized and freeze-dried collagen type I. This was assessed in a standardized minipig model.

MATERIAL AND METHODS

Implant materials

Algipore granules (0.5 × 1 mm) were obtained from Dentsply Friadent (Mannheim, Germany). Before implantation, the granules were mixed with blood according to the manufacturer's instructions. A paste suitable for application into the bone defects was prepared.

For Algipore modification (ACI), 2.5 wt% of mineralized collagen type I was added to the Algipore granules in lyophilized form and mixed with blood. Comparably, a pastelike consistency was created.

Mineralized collagen was prepared using a biomimetic process of synchronous fibrillation and mineralization of a collagen type I solution according to Bradt et al.[11] In brief, acid-soluble collagen type I isolated from calf skin (Collaplex 1.0, GfN, Wald-Michelbach, Germany) was dissolved in 10 mmol/L hydrochloric acid and mixed with a calcium chloride solution. The pH was adjusted to 7 by addition of TRIS and phosphate buffer and the mixture was heated to 37°C for 12 hours. Under these conditions, collagen fibril reassembly and nanocrystalline hydroxyapatite precipitation occur simultaneously. The product—a waxlike, colorless nanocomposite consisting of homogeneously mineralized collagen fibrils—was collected by centrifugation. The material was freeze-dried, ground to powder, and sterilized by γ-radiation.

Animal model

The research protocol of this study was approved by the Commission for Animal Studies at the District Government Office, Dresden, Germany. Ten female minipigs of the breed "Mini-Lewe" (aged 12 months, weight 105.3 ± 11.5 kg) were used for this study. The animals were killed after a healing period of 4 months.

Surgical procedures

All surgical procedures were performed under general anesthesia. After subcutaneous administration of 4 mg/kg body weight Stresnil (Janssen-Cilag GmbH, Neuss, Germany) for sedation, anesthesia was induced by intramuscular injection of 10 mg/kg body weight ketamine (Riemser Arzneimittel AG, Greifswald, Germany) and 2 mg/kg body weight xylazine (Riemser Arzneimittel AG). Subsequently, 0.4 mg/kg body weight diazepam (ratiopharm GmbH, Ulm, Germany) and 0.02 mg/kg body weight atropine (Eifelfango Chem.-Pharm.-Werke, Bad Neuenahr-Ahrweiler, Germany) were injected intramuscularly.

The frontal bone was exposed by placing a supraorbital midline incision with lateral relief incisions. A mucoperiosteal flap was elevated and 3 bone defects were placed in the external lamina of the frontal bone area by a trephine drill. Each defect had a diameter of 10 mm and a depth of 3 mm. To enable radiological detection, 4 micro titanium screws were inserted at the edges of each drill hole.

The first cavity was filled with Algipore and the second cavity with ACI. Immediately before application, the grafting material was mixed with the pig's autogenous blood and a paste suitable for insertion was prepared. The third defect served as a reference, having no grafting material. This defect spontaneously filled with blood. The mucoperiosteal flap was repositioned and the wound closure was performed using resorbable sutures (Vicryl 3 × 0, Ethicon, Norderstedt, Germany).

For postoperative analgesia, fentanyl (Janssen-Cilag GmbH, Neuss, Germany) was applied transcutaneously for 5 days. Prophylactic administration of clindamycin (Pfizer Deutschland GmbH, Berlin, Germany) was performed intra- and postoperatively. The minipigs were kept in animal facilities. Wound healing, food ingestion, and behavior were monitored daily.

Retrieval of specimens

After 4 months, the animals were killed under general anesthesia by intravenous injection of an overdose of T61 (embutramid, mebezonium, tetracaine) (Veterinaria AG, Pfäffikon, Switzerland). The soft tissues were removed and the frontal bone was dissected. The bone samples were fixed in 10% formaldehyde for 48 hours. For the radiological detection of the defects, the samples were covered with a titanium mesh and radiographic images (Orthophos, Sirona Dental Systems GmbH, Bensheim, Germany) of the frontal bone region were taken (Figure 1). The titanium screws allowed detection of the defects. Bone blocks of 20 × 20 mm containing the defects were dissected using a diamond saw.

Histologic preparation

After dehydration in a graded series of ethanol, all specimens were embedded in methylmethacrylate

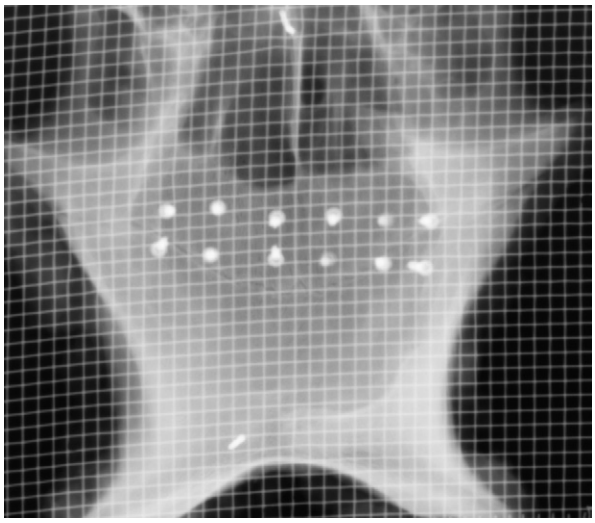

Fig. 1. Radiograph of the frontal bone with the defects marked by titan screws (Orthophos, Sirona Dental Systems).

(Technovit 9100 NEU, Heraeus Kulzer, Wehrheim, Germany) according to the manufacturer's instructions. Cross sections 500 μm thick of each defect were cut with a diamond saw system (Exakt-Mikro–Schleifsystem; Exakt-Apparatebau, Norderstedt, Germany) according to Donath's microsectioning and grinding technique.[17] The cross-sectional thickness was reduced to 50 μm using a roll grinder containing sandpaper with decreasing grain size (Exakt-Apparatebau, Norderstedt, Germany). Thus, 450 cross sections of 30 defects were obtained. Subsequently, the specimens were stained with Masson Goldner's trichrome stain.

Histologic examination

The samples were imaged using light microscopy (Olympus BX61, Olympus Deutschland GmbH, Hamburg, Germany). Multiple image alignment was possible using a scanning table (Märzhäuser, Wetzlar, Germany). Six images per defect were scanned under 10-fold magnification and fused to one image.

The histologic evaluation focused on potentially inflammatory reactions and on the qualitative evaluation of bone remodeling and resorption characteristics of the substitutes.

Histomorphometry was applied to quantify the amount of newly formed bone tissue within the defect areas. Therefore, volume fractions of trabecular bone, osteoid, and stroma within the defect were detected by color labeling and the percentage of the total defect area was calculated. The degree of resorption of the grafting materials was assessed by calculating the percentage of remnant parts of Algipore and ACI.

Statistics

Statistical analysis was performed using SPSS 15.0.1 (SPSS Inc., Chicago, IL). Mean values and SDs of the percentages of trabecular bone, osteoid, and stroma were calculated for each group. Comparing the differences of mean values, the pairwise Tukey-HSD test procedure was carried out. Mean values and SDs of remaining parts of Algipore and ACI were compared using the *t* test. A statistical level of significance was taken at $P = .05$.

RESULTS

All animals had an uneventful recovery without any signs of inflammation or infection over the entire observation period. Some animals showed exostosis in the area of the defects.

Histomorphology

Control. After 4 months of healing, control defects showed a spontaneous regeneration. All defects were filled with a spongious trabecular meshwork. As a sign of osteoblast activity, a thick layer of osteoid covered the trabeculae. Large areas of stroma could be found between the meshwork. Bone formation initiated from the host bone. There were no signs of inflammation (Figure 2).

Algipore. At the time of examination, most of the graft material was resorbed and replaced by newly formed bone. Compared with controls, the Algipore defects showed dense and mature bone structures with signs of remodeling. Appositional bone formation could be observed on the bone substitute surface. De novo bone formation started from the bone substitute surface. Appositional bone formation could be observed at the periost bone substitute interface. Only a few particles, located adjacent to periost, were partially covered by fibrous tissue. Remaining Algipore particles were integrated into bone. The granules showed a roughened surface structure with lacunae as sign of resorption. Neither signs of osteolysis nor inflammation could be observed (Figure 3).

Algipore-collagen. In defects filled with ACI, observations were comparable to Algipore. Graft particles were mostly resorbed. Most of the material was replaced by newly formed bone. The trabecular structure contained more spongious bone compared with adjacent host bone. Compared with controls, a dense meshwork of mature bone could be found. Osteoblast conglomeration could be found on implant bone interface, indicating bone formation. De novo bone synthesis started from host bone toward the implant surface. A pronounced osteoid layer was found at the interface of newly formed bone and host bone. Kissing contacts could be observed at the interface of remaining gran-

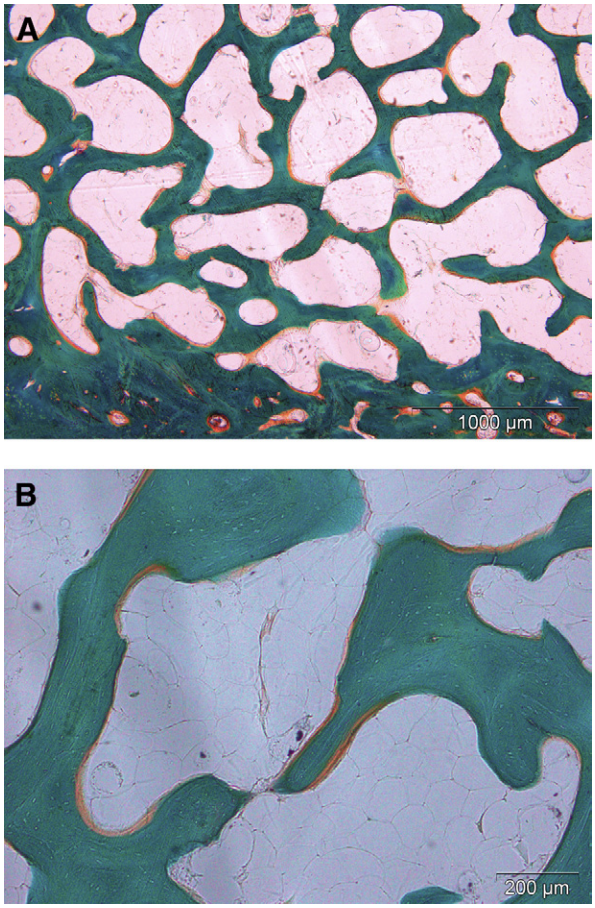

Fig. 2. **A,** Control defect interface host bone—newly formed bone (Masson-Goldner stain, original magnification ×40). **B,** Detail of Figure 2, *A*, showing a rarefied trabecular meshwork (Masson-Goldner stain, original magnification ×100).

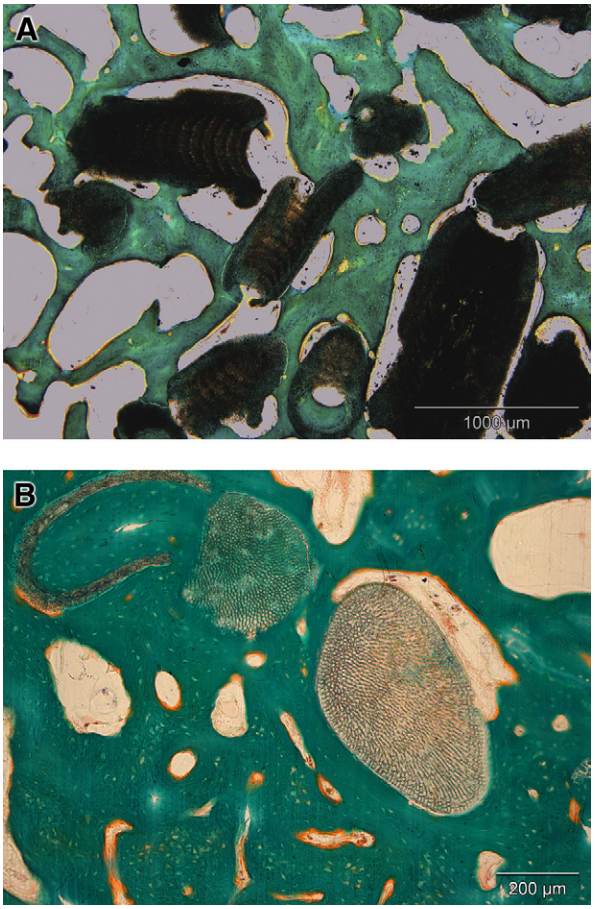

Fig. 3. **A,** Algipore particles embedded in mature trabecular bone (Masson-Goldner stain, original magnification ×40). **B,** Detail of Algipore particles in an advanced state of resorption (Masson-Goldner stain, original magnification ×100).

ules and surrounding bone. Most graft particles showed a rough surface structure with resorption lacunae containing osteoclasts. No indication for fibrous tissue coverage of graft particles, osteolysis, or inflammation could be found (Figure 4).

Histomorphometry

Results of the histomorphometric analysis are illustrated in Figure 5 and Table I. The fraction of mature trabecular bone was 58.9% for the defects filled with Algipore followed by the combination of Algipore and collagen I with 53.6%. There was a significant difference compared with the control of 42.2% ($P < .001$; $P = .013$). Defects filled with Algipore exhibited 4.8% osteoid, ACI exhibited 6.7% osteoid. The difference in control defects with 0.9% osteoid fraction was again significant for both grafting materials ($P = .001$). The fraction of stroma was 32.4% for defects grafted with Algipore and 35.4% for ACI. More stroma could be observed in control defects with 56.3%. Differences between control and both grafting materials reached significance ($P < .001$). Differences between the grafting materials were not significant.

Resorption characteristics

After 4 months, the remaining fractions were 42.2% for Algipore and 47.9% for the combination of Algipore and collagen I (shown in Figure 6). The difference between the grafting materials was significant ($P = .016$).

DISCUSSION

The aim of the present study was to evaluate the osseoconductive and resorptive characteristics of Algipore modified with mineralized and freeze-dried collagen type I.

Our results indicate that ACI shows osseointegration properties similar to commercially available Algipore. The histologic evaluation showed a meshwork of trabecular bone with pronounced osteoid layers. Signs of

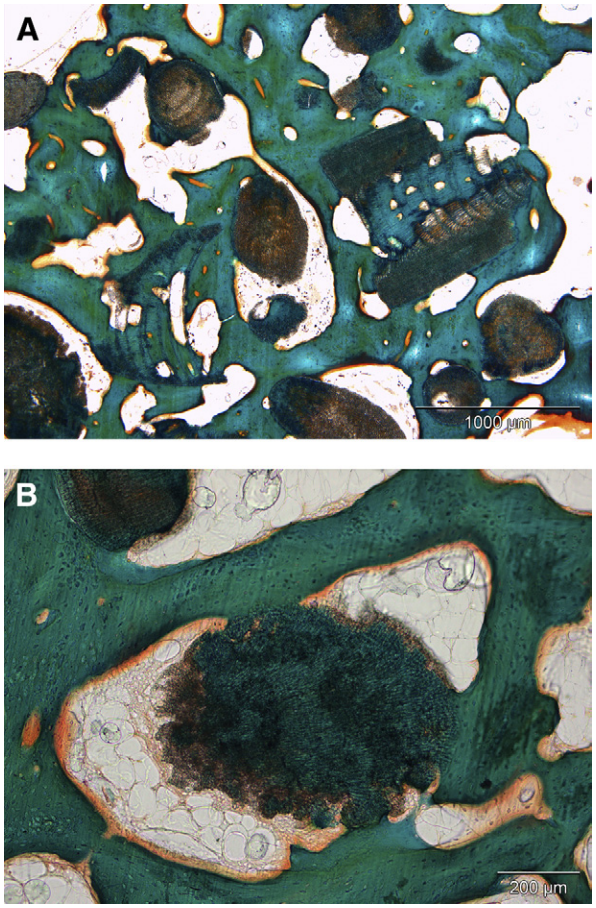

Fig. 4. **A,** Algipore collagen-filled defect with pronounced osteoid formation (Masson-Goldner stain, original magnification ×40). **B,** Algipore particle with a rough surface indicating resorption (Masson-Goldner stain, original magnification ×100).

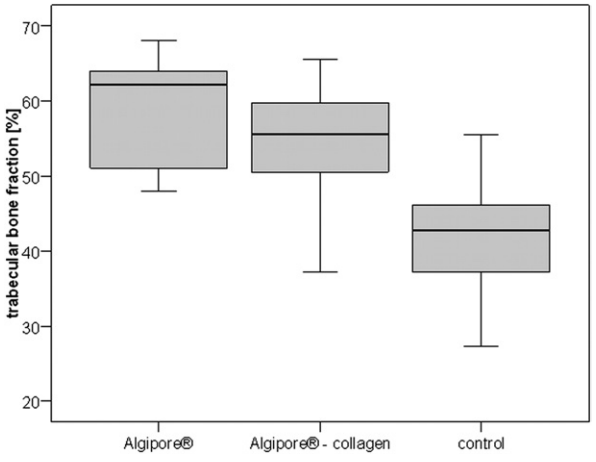

Fig. 5. Fractions of trabecular bone in substitute filled defects were significantly higher compared with control defects (Algipore: $P < .001$; ACI: $P = .013$).

Table I. Histomorphometric parameters, mean values, minimum, and maximum

	Control	*Algipore*	*ACI*
Trabecular bone, %			
Mean	42.2	58.9	53.6
Minimum	27.4	48.0	37.3
Maximum	55.5	68.1	65.5
Osteoid, %			
Mean	0.9	4.8	6.7
Minimum	0.3	2.3	2.5
Maximum	2.4	9.3	12.0
Stroma, %			
Mean	56.3	32.4	35.4
Minimum	41.2	20.5	26.0
Maximum	72.9	44.6	56.0

ACI, Algipore modified with collagen type I.

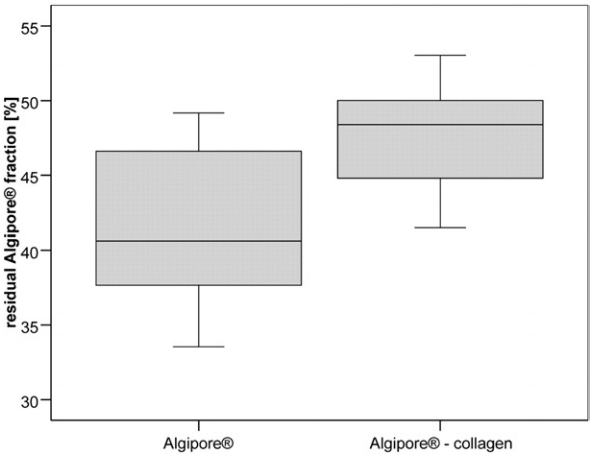

Fig. 6. Differences of residual substitute fractions were significant ($P = .016$).

inflammation or foreign body reactions could not be observed. Remaining graft particles were osseointegrated and not covered by fibrous tissue. These findings demonstrate a good biocompatibility of the modified substitute, causing no immunologic reactions. This is in accordance with other studies, where immunologic reactions of hydroxyapatite collagen composites could not be observed.[18] The histomorphometric results underline these histologic findings. Both grafting materials enhance bone formation significantly compared with controls. The osseoconductive properties of Algipore have been demonstrated in several animal and clinical studies.[8] The interconnecting microporous structure with a pore size of 10 µm is capable of allowing bone ingrowth in vivo. A good biocompatibility was equally observed.[9] In consequence, the hydroxyapatite (Algipore) used in the present study could be seen as proper for bone-bordered defects.

The second component, mineralized collagen I, is described to enhance proliferation and differentiation of

osteoblasts and progenitor cells in vitro.[19] Several in vivo studies showed positive results for the combination of hydroxyapatite and collagen. In combination with nanocrystalline hydroxyapatite cements, positive results for collagen I could be demonstrated in the mandible of minipigs.[16] Rammelt et al.[18] observed a significantly increased bone implant contact after 28 days in rat tibiae using a nanocrystalline hydroxyapatite collagen I cement. In contrast, Gabriellie et al.[20] found no bone formation in the zygomatic arch of rats after the implantation of a hydroxyapatite collagen I combination. In the present study, the osseoconductive properties of hydroxyapatite modified with collagen I were similar to those of pure Algipore; however, an increase in osseoconductive properties of ACI compared with Algipore could not be observed in the present study. The comparability of different studies is limited owing to different animals or implantation sites. Regarding the animal model, bone turnover rate in rats is higher compared with minipigs. In the present study, the minipig was chosen because of its similarity in bone turnover compared with humans. A defect of 10 mm in diameter and 3 mm in depth was placed, thus being no critical-size defect; however, it is not considered essential to apply critical size defects for the evaluation of osseoconductive properties of substitute materials.[21] This is further shown by Busenlechner et al.[22] using a defect of 10 mm in diameter and 8 mm in depth in porcine calvaria.

One important characteristic of graft materials is the replacement by living bone. After 4 months of healing, more than half of the implanted materials were resorbed. The remaining particles were integrated in the bone structure. These findings are in accordance with Yokoyama et al.,[15] who evaluated hydroxyapatite-collagen I composites in rats. After 12 weeks, the major part of the bone substitute was replaced. Resorption of the graft material usually begins shortly after insertion; however, in human biopsies residual particles of Algipore could still be observed 6 years after implantation.[8] Currently, healing periods between 6 and 7 months for grafted sites are recommended before implant insertion.[8] Fostering resorption of graft material and formation of new bone could reduce this time. Accelerated bone formation would allow a contemporary implant insertion. Therefore, time required for rehabilitation would be reduced. ACI showed a slower resorption compared with pure Algipore. After 4 months, a significant fraction of remnants could be seen in defects filled with ACI. This indicates that mineralized collagen I decelerates the replacement of Algipore granules. Thus, placement of dental implants would be prolonged likewise and clinical benefit is doubtful.

In conclusion, the present study showed that Algipore modified with mineralized and freeze-dried collagen type I enhances bone formation in calvarial defects of minipigs. This was comparable with the characteristics of commercially available Algipore. Increased osseoconductive properties or degrees of resorption in comparison with pure Algipore could not be observed in this study.

The authors are grateful to Mrs. Ines Kleiber for preparing the histologic samples and Mrs. Ortrud Zieschang for preparation of mineralized collagen.

REFERENCES

1. Scales JT. Discussion on metals and synthetic materials in relation to soft tissue: tissue reactions to synthetic materials. Proc R Soc Med 1953;46:647–2.
2. Sen MK, Miclau T. Autologous iliac crest bone graft: Should it still be the gold standard for treating nonunions? Int J Care Injured 2007;38:S75-S80.
3. Khan SN, Camissa FP Jr, Sandhu HS, Diwan AD, Girardi FP, Lane JM. The biology of bone grafting. J Am Acad Orthop Surg 2005;13:77-86.
4. Mazock JB, Schow SR, Triplett RG. Posterior iliac crest bone harvest: review of technique, complications, and use of an epidural catheter for postoperative pain control. J Oral Maxillofac Surg 2003;61:1497-503.
5. Wippermann BW, Schratt HE, Steeg S, Tscherne H. [Complications of bone harvesting at the iliac crest. Retrospective analysis of 1191 cases.] Chirurg 1997;68:1286-91. German.
6. Ewers R, Kasperk C, Simons B. [Biological bone implants of sea algae.] Zahnarztl Prax 1987;38:318-20. German.
7. Cvikl B, Turhani D, Kapral D, Weiβenböck M, Thurnher D, Item C, et al. In-vitro study on osteoblast-like cells cultivated on phycogene hydroxyapatite ceramic. Dtsch Zahnärztl Z 2004;59: 567-71.
8. Ewers R. Maxilla sinus grafting with marine algae derived bone forming material: a clinical report of long-term results. J Oral Maxillofac Surg 2005;63:1712-23.
9. Schopper C, Moser D, Sabbas A, Lagogiannis G, Spassova E, König F, et al. The fluorohydroxyapatite (FHA) FRIOS Algipore is a suitable biomaterial for the reconstruction of severely atrophic human maxillae. Clin Oral Implants Res 2003;14:743-9.
10. Lynch MP, Stein JL, Stein GS, Lian JB. The influence of type I collagen on the development and maintenance of the osteoblast phenotype in primary and passaged Rat calvarial osteoblasts: modification of expression of genes supporting cell growth, adhesion, and extracellular matrix mineralization. Exp Cell Res 1995;216:35-45.
11. Bradt JH, Mertig M, Teresiak A, Pompe W. Biomimetic mineralization of collagen by combined fibril assembly and calcium phosphate formation. Chem Mater 1999:2694–701.
12. Domaschke H, Gelinsky M, Burmeister B, Fleig R, Hanke T, Reinstorf A, et al. In vitro ossification and remodeling of mineralized collagen I scaffolds. Tissue Eng 2006;12:949-58.
13. Bernhardt A, Lode A, Boxberger S, Pompe W, Gelinsky M. Mineralised collagen—an artificial, extracellular bone matrix—improves osteogenic differentiation of bone marrow stromal cells. J Mater Sci Mater Med 2008;19:269-75.
14. Bernhardt A, Lode A, Mietrach C, Hempel U, Hanke T, Gelinsky M. In vitro osteogenic potential of human bone marrow stromal cells cultivated in porous scaffolds from mineralized collagen. J Biomed Mater Res A 2009;90:852-62.

15. Yokoyama A, Gelinsky M, Kawasaki T, Kohgo T, Konig U, Pompe W, et al. Biomimetic porous scaffolds with high elasticity made from mineralized collagen—an animal study J Biomed Mater Res B J Appl Biomater 2005;75:464-72.
16. Mai R, Reinstorf A, Pilling E, Hlawitschka M, Jung R, Gelinsky M, et al. Histologic study of incorporation and resorption of a bone cement-collagen composite: an in vivo study in the minipig. Oral Surg Oral Med Oral Pathol Oral Radiol Endod 2008; 105:e9-14.
17. Donath K, Breuner G. A method for the study of undecalcified bones and teeth with attached soft tissues. The Säge-Schliff (sawing and grinding) technique. J Oral Pathol 1982;11:318-26.
18. Rammelt S, Schulze E, Witt M, Petsch E, Biewener A, Pompe W, Zwipp H. Collagen type I increases bone remodelling around hydroxyapatite implants in the rat tibia. Cells Tissues Organs 2004;178:146-57.
19. Mizuno M, Fujisawa R, Kuboki Y. Type I collagen-induced osteoblastic differentiation of bone-marrow cells mediated by collagen-alpha2beta1 integrin interaction. J Cell Physiol 2000;184:207-13.
20. Gabrielli MA, Marcantonio Júnior E, Góissis G, Okamoto T, Gabrielli MF, Vieira EH. Hydroxylapatite implants with or without collagen in the zygomatic arch of rats. Histological study. Braz Dent J 2001;12:9-15.
21. Schlegel KA, Lang FJ, Donath K, Kulow JT, Wiltfang J. The monocortical critical size bone defect as an alternative experimental model in testing bone substitute materials. Oral Surg Oral Med Oral Pathol Oral Radiol Endod 2006;102:7-13.
22. Busenlechner D, Tangl S, Fitzl C, Bernhart T, Gruber R, Watzek G. Paste-like inorganic bone matrix: preclinical testing of a prototype preparation in the porcine calvaria. Clin Oral Implants Res 2009;20:1099-104.

Reprint requests:

Matthias C. Schulz, DMD
Department of Oral and Maxillofacial Surgery
Faculty of Medicine
"Carl Gustav Carus" Technische Universität, Dresden
Fetscherstraße 74, D-01307 Dresden, Germany
matthias.schulz@uniklinikum-dresden.de